

Radiology-guided forceps biopsy and airway stenting in severe airway stenosis

Zong-Ming Li, Gang Wu, Xin-Wei Han, Ke-Wei Ren, Ming Zhu

PURPOSE

We aimed to determine the feasibility, safety, and effectiveness of radiology-guided forceps biopsy and airway stenting in patients with severe airway stenosis.

MATERIALS AND METHODS

This study involved 28 patients with severe airway stenosis who underwent forceps biopsy between October 2006 and September 2011. Chest multislice computed tomography was used to determine the location and extent of stenosis. Sixteen patients had tracheal stenosis, two patients had stenosis of the tracheal carina, six patients had stenosis of the left main bronchus, and four patients had stenosis of the right main bronchus. Forceps biopsy and stenting of the stenosed area were performed under fluoroscopic guidance in digital subtraction angiography and the biopsy specimens were analyzed histopathologically. We contacted the patients via phone call and utilized a standardized questionnaire to determine their medical condition during a postoperative three-month follow-up.

RESULTS

The technical success rate of radiology-guided forceps biopsy was 100%. Biopsy specimens were obtained in all patients. Dyspnea was relieved immediately after stent placement. No serious complications, such as tracheal hemorrhage or perforation, mediastinal emphysema, or asphyxia, occurred.

CONCLUSION

Radiology-guided forceps biopsy and airway stenting can be used for the emergency treatment of severe airway stenosis. This method appears to be safe and effective, and it may be an alternative therapeutic option in patients who cannot tolerate fiberoptic bronchoscopy.

Dyspnea due to severe airway stenosis is a serious, acute respiratory condition that can cause death due to asphyxiation. In patients with moderate airway stenosis, fiberoptic bronchoscopy and biopsy can be used to determine the underlying disease pathology and direct further treatment (1). However, bronchoscopy and biopsy are difficult in patients with severe airway stenosis, especially in those with a highly vascular stenosed segment. A severely stenosed airway may be too narrow to allow the insertion of a fiberoptic bronchoscope; moreover, there is a risk of hemorrhage during the bronchoscopy and biopsy. Such patients have difficulty in breathing, and may even choke to death. This retrospective analysis involved 28 patients with severe airway stenosis who underwent forceps biopsy in our Department of Interventional Radiology. Timely placement of airway stents can release airway strictures and relieve dyspnea (2, 3).

Materials and methods

Patients

Between October 2006 and September 2011, 28 patients, including 17 men and 11 women, with a mean age of 56.3 ± 11.4 years (range, 26–78 years) were admitted to the emergency department of our hospital with severe dyspnea that precluded any physical activity and prevented breathing in the supine position, forcing the patients to maintain a sitting posture. On physical examination, all patients were found to have cyanosis of the lips, sweating, retraction sign of three fossae (retraction of supraclavicular fossa, suprasternal fossa, and intercostal spaces), and stridor. Chest multislice computed tomography (MSCT) showed severe tracheal stenosis in 16 patients, tracheal carina stenosis in two patients, right main bronchial stenosis in four patients, and left main bronchial stenosis in six patients. Using mediastinal window of MSCT, we found that the narrowest airway lumen diameter was 2–4 mm. Routine fiberoptic bronchoscopy showed that the stenosed segment was highly vascular in 12 patients, and thus, bronchoscopic biopsy was not performed because of the risk of asphyxiation due to bleeding. The remaining 16 patients had severe orthopnea and could not tolerate fiberoptic bronchoscopy in the supine position.

Devices

We used the following equipment: tooth cushions, 5 F (0.038-inch) multipurpose catheter (Terumo Holding, Beijing, China), hydrophilic guidewire (0.035 inches \times 260 cm), 10 F long sheath (Cook Medical, Bloomington, Indiana, USA), endoscopic biopsy forceps, self-expanding airway stents (Micro-tech, Nanjing, China).

From the Department of Interventional Radiology (X.W.H.
✉ hanxinwei2006@163.com), the First Affiliated Hospital of Zhengzhou University, Zhengzhou, China.

Z.M.L. and G.W. contributed equally to this work and share first authorship.

Received 15 November 2012; revision requested 4 December 2012; final revision received 25 November 2013; accepted 25 December 2013.

Published online 30 April 2014.
DOI 10.5152/dir.2014.12118

Digital subtraction angiography (DSA) was performed using the Artis Zeego system (Siemens, Erlangen, Germany). MSCT was performed using the GE LightSpeed RT 16 (GE Healthcare, Milwaukee, Wisconsin, USA), GE LightSpeed VCT 64-slice (GE Healthcare), and Philips Brilliance 16 CT scanner (Philips Healthcare, Best, the Netherlands).

Preoperative preparation

The preoperative workup consisted of routine blood examination, electrolyte assay, electrocardiogram (ECG), and chest MSCT to localize the airway stricture, determine its length, severity, and cause, and individualize airway stent measurements (Fig. 1). All patients were administered anti-inflammatory (cefoperazone sodium injections, 4.0 g/day) and expectorant (ambroxol hydrochloride injections, 90 mg/day) drugs to prevent thick sputum and pus from blocking the airways. Dehydrating agents (furosemide 20–40 mg/day, intravenously) and glucocorticoids (dexamethasone 10 mg/day, intravenously) were used to reduce edema at the site of stenosis, relieve dyspnea and improve patient tolerance to bronchoscopy. The intraoperative, noninvasive administration of high-flow oxygen, so that the SpO₂ is maintained above 95%, provided sufficient time to operate, eliminating the need for general anesthesia.

X-ray-guided forceps biopsy and airway stenting

Lying on the bed of the DSA system, patients were administered high-flow oxygen through a nasal cannula, and their ECG, blood oxygen saturation, blood pressure, heart rate, and respiration were monitored. The throat and trachea were sprayed with lidocaine to provide surface anesthesia. Under fluoroscopic guidance, a multipurpose catheter was passed over a hydrophilic guidewire through the mouth and throat, into the trachea. As contrast agent, ioversol (3–5 mL) was injected from catheter below the stenosis area to display the location and extent of the stenosis, and to determine the length of the stenosis accurately (Fig. 2a). Lidocaine (2–3 mL) was injected in the tracheal carina to inhibit the cough reflex and reduce irritation. The catheter

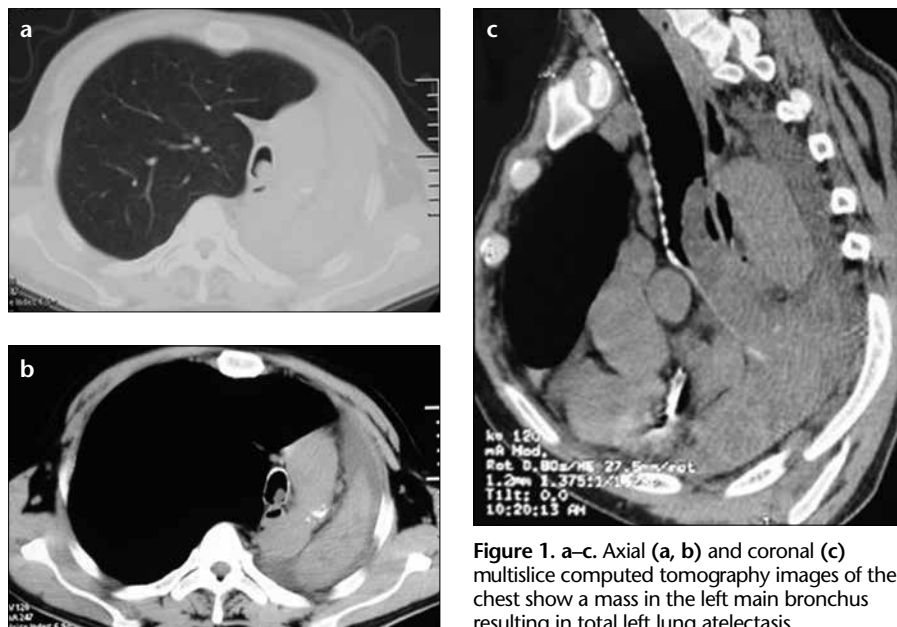


Figure 1. a–c. Axial (a, b) and coronal (c) multislice computed tomography images of the chest show a mass in the left main bronchus resulting in total left lung atelectasis.

was then advanced into the left or right main bronchus, and the hydrophilic guidewire was exchanged with a strengthened guidewire (the inverted, Y-shaped stent needs two strengthened guidewires positioned in the left and right main bronchi, with the stem of the “Y” in the trachea). The catheter was then removed, and a long sheath was introduced over the strengthened guidewire to the site of airway stenosis; a biopsy forceps was then introduced through the sheath (4, 5). Under fluoroscopic guidance, two or three grain-sized specimens were obtained from different parts of the stenosed area for histopathological analysis (Fig. 2b). An appropriate model of airway stent was selected depending on the location and extent of the stenosis, and the stent and its delivery system were inserted over the guidewire and through the sheath (Fig. 2c). Once the stent was in position, the sheath was removed and the stent was rapidly expanded. The stent delivery system was then removed. A catheter was again passed over the guidewire to the stent, and the guidewire was removed. Adrenaline (2–3 mL) was injected through the catheter to stop or prevent bleeding. Finally, the catheter was removed, and the procedure was completed.

Postoperative treatment and follow-up

Chest MSCT (Fig. 3) was performed one week postoperatively to observe the inflation of the stent. After the procedure,

the patients’ vital signs were monitored, and the presence or absence of hemoptysis and extent of relief from dyspnea were noted. Anti-inflammatory and expectorant drugs, as well as aerosol inhalation (20 mL saline, 5 mL 2% lidocaine, 0.2 g amikacin, 5 mg dexamethasone, and 8000 U chymotrypsin) were routinely prescribed to eliminate pain, irritation, and local inflammation due to the foreign body (stent). Further treatment was administered according to the pathological findings.

We contacted the patients via phone call and utilized a standardized questionnaire to interview them regarding their medical condition during a postoperative three-month follow-up. Questions included the following: Is the patient still alive? If so, does the patient have any respiratory complications? Does the patient have any fever and/or weight changes?

Results

Fluoroscopy-guided biopsy and airway stenting were performed successfully, in all patients with airway stenosis (n=28). Tracheal self-expandable tube stents were placed in 15 patients; inverted Y-shaped, integrated tracheal-main bronchi stents were placed in 11 patients; and L-shaped, tracheal-left main bronchus stents were inserted in two patients. The entire procedure was performed in 3–5 min, and all stents were successfully placed at the first attempt. No procedure-related

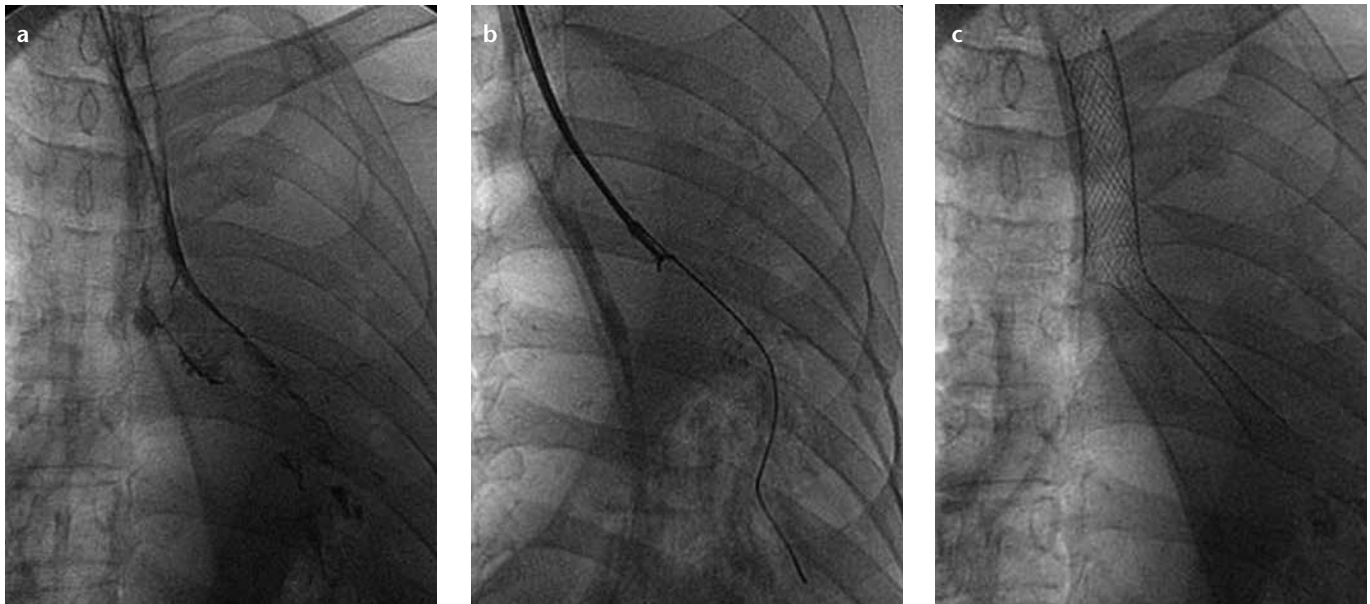


Figure 2. a–c. Fluoroscopic images show airway obstruction (a), biopsy forceps inserted in the left main bronchus (b), and L-shaped stent inserted in the trachea and left main bronchus (c).

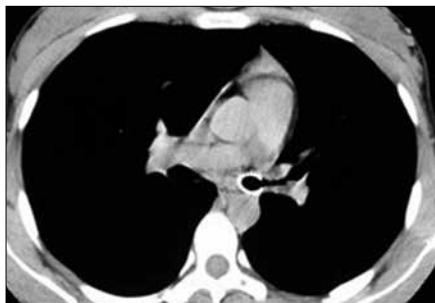

Figure 3. Postoperative multislice computed tomography image of the chest shows complete inflation of the stent.

complications, such as airway bleeding, choking, airway wall rupture, or pneumothorax, occurred. After airway stenting, dyspnea was immediately alleviated, cyanosis and retraction sign of three fossae disappeared, and the patients were able to breathe in the supine position or even get out of bed. Patients experienced some discomfort after airway stenting, such as varying degrees of retrosternal pain, coughing, expectoration, and blood-stained sputum. All patients received symptomatic treatment with anti-inflammatory and expectorant drugs and aerosol inhalation, which gradually lessened or relieved the above symptoms over 3–7 days. Further treatment was administered according to the pathological examination results of the biopsy specimens. The biopsy results revealed squamous cell carcinoma (n=19), lung adenocarcinoma (n=2), tracheal ade-

noid cystic carcinoma (n=2), chronic inflammation (n=2), neuroendocrine adenocarcinoma (n=1), thymoma infiltrating the airway wall (n=1), and severe dysplasia (n=1).

At three-month follow-up, all patients were alive with no severe intra- or postoperative complications related to the airway stent placement, such as asphyxia, hemorrhage, or airway rupture. Two patients with pathological findings of chronic inflammation were diagnosed with inflammatory granulomas, and both recovered after bronchoscopic treatment. Other patients improved upon management with appropriate conservative treatments.

Discussion

Severe airway stenosis can be caused by airway tumors, mediastinal tumors, metastases, esophageal cancer violation of the trachea, airway membrane tuberculosis, chest trauma and emergency tracheotomy, tracheal collapse, concurrent cicatricial stenosis, and a variety of benign and malignant lesions. If not treated in a timely manner, airway stenosis can be fatal (6). Mild-to-moderate airway stenosis is not life-threatening and does not impede patient tolerance to bronchoscopy. Endobronchial biopsy under direct vision is possible in these patients, and a number of effective treatment options are available. In contrast, severe airway stenosis causes

great difficulty in breathing, including orthopnea. The primary aim of treatment in such patients is to release the stenosis in order to recover ventilatory function and save the patient's life; obtaining a pathological specimen is not a priority in these cases. Accordingly, the underlying pathology may not be identified, hampering effective treatment and causing long-term effects.

Currently, most biopsies of the respiratory tract are performed bronchoscopically under direct vision (7–8). The approach is not suitable for patients with severe airway stenosis (9). In mild-to-moderate airway stenosis, fiberoptic bronchoscopy can be used to visualize the entire lesion, determine the location and extent of the stenosis, obtain biopsy specimens, and administer local tumor ablation therapy. In severe airway stenosis, however, the fiberoptic bronchoscope cannot be passed through the stenosed segment and details about the stenosed segment cannot be ascertained, especially vascularity of the stenosed segment, leading to a high risk of hemorrhage, which may be difficult to control and even cause death due to asphyxiation (10, 11). Therefore, fiberoptic bronchoscopy is a high-risk procedure in patients with severe airway stenosis. Airway stenting can mitigate severe airway stenosis, but makes biopsy difficult because the stent covers the lesion.

Chest MSCT has been used to assess the location and extent of stenosis, and to examine the adjacent tissues. Interventional radiology technology has been used to introduce vascular sheaths over the guidewire, and biopsy specimens have been successfully obtained by inserting biopsy forceps through the vascular sheath in patients with biliary tract and severe esophageal stenosis (4, 5). We performed fluoroscopy-guided forceps biopsy through the vascular sheath in patients with severe airway stenosis, with accurate localization and high technical success, safety, and effectiveness to rapidly obtain samples for histopathological analysis. Airway stents were placed immediately after acquisition of the pathological material. Self-expanding airway stents were used to expand the lesions, as these stents are useful in achieving hemostasis. Moreover, blood in the airway is easily expelled after hemoptysis, minimizing the risk of mortality from asphyxiation due to bleeding. None of the study patients experienced intra- or postoperative hemorrhage, choking, or other serious complications. Biopsy using interventional radiology techniques is similar in principle to a bronchoscopic biopsy under direct vision, except for the monitoring method. Airway stent placement immediately after radiology-guided biopsy shortens the operation time and decreases the patient's suffering.

Chest pain, foreign body sensation and cough were observed in most patients at one week postoperatively, which may be a result of not tight enough attachment between airway and the stent, although all stents were appropriately expanded during the procedure. Postoperative week one is the peak time for stent migration.

We consider that radiology-guided airway biopsy is indicated for diagnostic assessment and emergency treatment of severe airway stenosis, when

the stenosed segment is highly vascular or there is a high risk of bleeding for any reason and when fiberoptic bronchoscopy or bronchoscopic biopsy fails. The disadvantages of this technique include the inability to repeat the biopsy after stent placement if pathological examination results come back negative and its applicability to lesions within the airway lumen only.

In patients with severe airway stenosis, the insertion of a catheter, guidewire, and stent delivery system into the already narrowed airway will further increase the stenosis, and therefore, stent implantation should be completed within a short period of time. This requires accurate and rapid stent deployment, adequate intraoperative anesthesia, high-flow oxygen, and transcatheter epinephrine administration in the airway before and after stent implantation. Some authors advocate endotracheal stenting under general anesthesia, but severe airway stenosis, particularly if it involves the trachea, tracheal carina, or main bronchi, cannot be treated using endotracheal intubation and anesthesia. We found that the intraoperative transcatheter injection of anesthetic agents in the tracheal carina inhibits the cough reflex and reduces irritation.

In conclusion, fluoroscopy-guided forceps biopsy and airway stent implantation appears to be safe and effective in patients with severe airway stenosis. This procedure can relieve airway obstruction in an emergency setting and help provide a pathological diagnosis, which in turn can direct subsequent treatment. We believe that this procedure may have wide applications.

Conflict of interest disclosure

The authors declared no conflicts of interest.

References

1. Dooms C, Seijo L, Gasparini S, Trisolini R, Ninane V, Tournoy KG. Diagnostic bronchoscopy: state of the art. *Eur Resp Rev* 2010; 19:229–236. [\[CrossRef\]](#)
2. Gaafar AH, Shaaban AY, Elhadidi MS. The use of metallic expandable tracheal stents in the management of inoperable malignant tracheal obstruction. *Eur Arch Otorhinolaryngol* 2012; 269:247–253. [\[CrossRef\]](#)
3. Kim WK, Shin JH, Kim JH, Song JW, Song HY. Management of tracheal obstruction caused by benign or malignant thyroid disease using covered retrievable self-expandable nitinol stents. *Acta Radiol* 2010; 51:768–774. [\[CrossRef\]](#)
4. Kawashima H, Itoh A, Ohno E, Goto H, Hirooka Y. Transpapillary biliary forceps biopsy to distinguish benign biliary stricture from malignancy: how many tissue samples should be obtained? *Dig Endosc* 2012; 24:22–27. [\[CrossRef\]](#)
5. Kasuga A, Yamamoto Y, Fujisaki J, et al. Clinical characterization of gastric lesions initially diagnosed as low-grade adenomas on forceps biopsy. *Dig Endosc* 2012; 24:331–338. [\[CrossRef\]](#)
6. Yu SY, Liu YH, Hsieh MJ, Ko PJ. Temporary stenting of acute airway stenosis with endotracheal tube—an effective method. *Int J Chin Pract* 2010; 64:103–105. [\[CrossRef\]](#)
7. Chrissian A, Misselhorn D, Chen A. Endobronchial-ultrasound guided miniforceps biopsy of mediastinal and hilar lesions. *Ann Thorac Surg* 2011; 92:284–288. [\[CrossRef\]](#)
8. Iwano S, Imaizumi K, Okada T, Hasegawa Y, Naganawa S. Virtual bronchoscopy-guided transbronchial biopsy for aiding the diagnosis of peripheral lung cancer. *Eur J Radiol* 2011; 79:155–159. [\[CrossRef\]](#)
9. Xie HB, Cornwell R, Grossman JE, Hoerl HD, Kurtycz DF. Bronchoscopy-guided transtracheal and transbronchial fine-needle aspiration biopsy: a 5-year institutional review of 111 cases. *Diagn Cytopathol* 2002; 27:276–281. [\[CrossRef\]](#)
10. Wahidi MM, Rocha AT, Hollingsworth JW, Govert JA, Feller-Kopman D, Ernst A. Contraindications and safety of transbronchial lung biopsy via flexible bronchoscopy. A survey of pulmonologists and review of the literature. *Respiration* 2005; 72:285–295. [\[CrossRef\]](#)
11. Pajares V, Torrego A, Puzo C, Lerma E, Gil De Bernabé MA, Franquet T. Transbronchial lung biopsy using cryoprobes. *Arch Bronconeumol* 2010; 46:111–115. [\[CrossRef\]](#)